

An efficient approach on optic disc detection and retinal blood vessel segmentation for diabetic retinopathy based on support vector machine

Prakash NB^{1*}, Hemalakshmi GR², Stella Inba Mary M²

¹Department of Electrical and Electronics Engineering, National Engineering College, Kovilpatti, Tamilnadu, India

²Department of Computer Science Engineering, National Engineering College, Kovilpatti, Tamilnadu, India

*Corresponding author: E-Mail: nbprakas@gmail.com, Mob: 9443414744

ABSTRACT

In this paper, Diabetic retinopathy is a disease of the eye and common complication of diabetes that can cause blindness if left undiagnosed at a preliminary stage. This work examines the optic disc (OD) detection, blood vessel segmentation approaches in retinal images developed from a fundus camera and analysis of methods is presented. Any automated tool for the analysis of diabetic retinopathy must go through following steps. First, it has to reveal major anatomical structures of the retina namely optic disc, fovea and blood vessels. Secondly, to identify the defect in the retina of the eye secretions such as solid, cotton wool spots, and microaneurysms bleeding caused by diabetic retinopathy. Soft computing techniques for anatomical structure detection and blood vessel segmentation of retinal images using MATLAB were implemented. Localization of the optic disc detection and blood vessel segmentation with the proposed methods yielded high accuracy compared with existing methods. A non-proliferative diabetic retinopathy, occurs when the blood vessels of the retina begin to bleed or leak fluid. The support vector machine (SVM) classifier has been proposed for analysis of diabetic retinopathy with MATLAB program and image processing techniques.

KEY WORDS: Diabetic Retinopathy, SVM, Feature extraction, Image Segmentation.

1. INTRODUCTION

In some people with DR, blood vessels might swell and outflow fluid. In other set of people, abnormal new blood vessels develop on the surface of the retina. The retina is the light-sensitive tissue at the back of the eye. Fundus is the individual part of the human body, as can be realized microcirculation openly. Diameter of blood vessels in entire parts of the optic disc is about 150 microns, and ophthalmoscope tolerates intensive care of the blood vessels with diameters as small as 10 microns (Morita, 2010).

The functions of the human eye, such as the camera. Human eye receives light, converted to an electrical signal and transmit the same to the brain with the help of the optic nerve, where the electrical signal is converted to a vision. Figure 1 shows a segment of the human eye and refers to its main components. Between the various structures of the eye, and explained only anatomical parts of the retina, which are more suitable for this research work. Light enters the human eye through the pupil and went on the retina similar to a film camera. Such as film, composed of several layers of the retina with different functions. The first layer that receives light on a layer of nerve fibers (Yau, 2012). Most of the blood vessels in the retina of the eye under this layer that nourish the inner parts of the retina. The outer layer contains millions of photoreceptors responsible for receiving light rays and converts them into electrical impulses. These are converted into electrical impulses images when it travels to the brain.

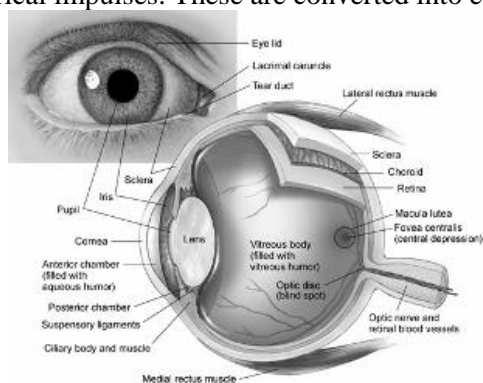


Figure.1. Anatomy of the Eye

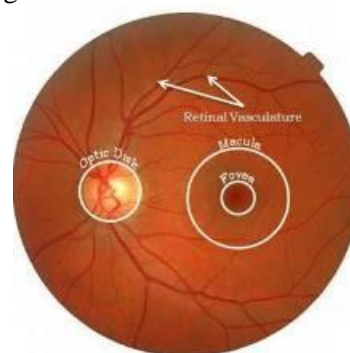


Figure.2. Retinal Image Showing Retinal Vasculature, Optic Disk, Macula and Fovea

The optic disc (or optic nerve head) is a bright yellowish disc, and that the blood vessels and nerve fibre optic emerge. Optic Disc sends electrical impulses from the retina to the brain, and it is about 3mm to nose fovea. It measures 1.5 to 2 mm in diameter. The blood vessels in the retina originated of the central artery and vein network, which lies in the optic nerve head (Zhang and Saaddine, 2010). These blood vessels sustain the inner parts of the retina and emit out from the optic disc. Figure 2 shows the image of the retina typical natural areas with the most prominent optic disc, fovea, macula and blood vessels. Diabetic retinopathy is a complication of diabetes on the retina. Symptoms of

microaneurysms, haemorrhages exudates in the very early stages may lead to diabetic retinopathy if not treated lasting for a long time. The problem here is that patients who may not be acquainted with it until it reaches advanced stages.

Literature Survey: Generally several studies on the division of the blood vessels, however, associated with only a small number of them to the blood vessels in the retina. In order to review the proposed methods to sector vessels in retinal images, has considered seven categories of methods: matched filters, tracking ship and morphological processing, and the region is growing, multi-domain, and approach the threshold oversees the adaptation. Effective localization of the optical disk and contour detection are most important tasks of diabetic retinopathy in screening automation system (Hammes, 2011). Localization of the optic disc is required as a prerequisite for success in many of the phases of the application of algorithms for identifying and dividing the anatomical and pathological structures in the images of the retina. Precise localization of the optic disc contour are very useful in the detection of proliferative diabetic retinopathy. Because of circulatory problems occurred during the early stages of diabetic retinopathy, and will be the development of new blood vessels, which are very sensitive and vulnerable to a large extent in the region, the optic disc in the retina of the eye. If the site was known to the optic disc, then the position of the other areas of medical importance, such as spot and fovea can be determined. Site optic disc can be used as a marker for image recording retina. As the optic disc or optic nerve head is the main source of retinal vessels, its center may be used as a starting point to track the approach. It has been proposed many schemes to resettle the optic disc. Most of these schemes have been found only on the optic disc and not address the problem of detecting the contour of the optic disc. Precise Localization of the optic disc surprisingly complex, because of its appearance is highly variable in the bottom of the image.

Algorithms localization of the optic disc through the creation of the largest collection of pixel values of the image and presence of high density. Characterized by the existence of a point greater than the density variation as the location of the optic disc. This algorithm does not consider the existence of retinal images bright lesions. However, retinal images with minor lesions may contemplate. Hybrid method has been used to restrict optical disk based on the intensity and structures a ship-based structure. First, it was derived optic disk filter sites based on information curvature that was used to detect the type of hill topographic feature which encodes inherently density features. Accordingly, it was measured a filter site possessing the maximum value of the optical disk (Barber, 2011). First, the extents were selected optical disk filter by classifying all the bright regions in the backgrounds. Secondly, it was to get on the blood vessels using binary plan proposed by Zhang. Related with other sections bright, and the optical disk has advanced fractal dimension because it is in the section of the optical disk will take part all major blood vessels. The proposed method by Osareh conducted local contrast enhancement to improve both contrast lesions on the back and color saturation. This was followed by a Support Vector Machine (SVM) compilation of sector potential filters secretions. Multilayer neural receptors with the network were used to classify the inputs ten filters secretions from non-secretions. This method achieved a sensitivity of 92% and specificity of 82%. The same authors used SVMs to classify filters secretions from non-secretions and resulted in sensitivity and specificity of 87.5% and 92%, respectively (Colagiuri, 2011). The algorithm proposed Sopharak used to collect secretions SVM slice images of the retina is dilated. Four features were the dominant hue, standard deviation, and the intensity of the edge of the adjustment by SVM for coarse segmentation followed by fine segmentation using morphological reconstruction.

2. EXPERIMENTAL

Methodology: The image is analyzed retinal color input and automatically derives a comprehensive assessment of the severity of diabetic retinopathy and macular edema after analysis. Image analysis system consists of the bottom of the proposed six key elements. It is used as a dualistic vascular component extracted by segmentation of blood vessels in the recognition of the optic disc, fovea detection and red lesion detection. Created find the localization of optical disk contour detection and location and boundaries of the optic disc (Sun, 2011). The site works optic disc to remove any false discoveries lesion bright optical disk. Fovea detection component detects blood vessels and corridors, and slick fovea.

Analysis of cell-free translation of diabetic retinopathy perfusion is limited to the display area image base, and the loss of early and progressive network of capillaries cells, including endothelial cells and pericytes, and inevitably leads to the obstruction of blood vessels and microaneurysms (Aiello, 2011). Cells die capillaries in the retina of the doubt in the case of diabetes and loss of cells, the effect of large vessels retinal proliferative incidence of diabetic retinopathy (PDR) occur before long, however, the death of capillary cells, especially cells in the peripheral, has found to be rare or absent from the capillary optic nerves and the brain. Perhaps this is evidence that the damage to the hair cells in the retina of the eye may be due to the disappearance of local, rather than systemic, such as high blood vessel.

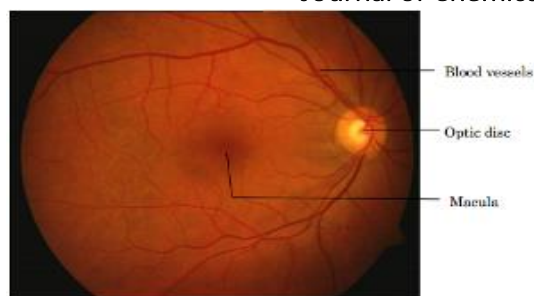

Figure.3. Anatomical structures of ocular fundus

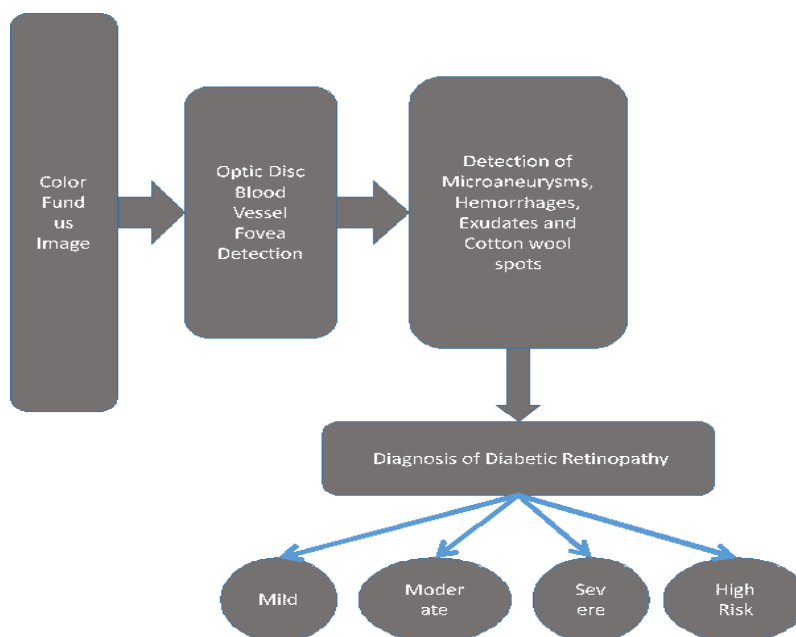


Figure.4. Fundus Image Analysis System

However, it has proven induced hyperglycemia apoptotic cells between *in vivo* and *in vitro* evidence for use in the laboratory when fluctuations in blood glucose levels and normal blood sugar and ultra-often occurs in poorly controlled diabetes mellitus and hyperglycemia sufficient to increase the retina, which in turn can also lead to the closure of the capillary basement membrane components of the cell death with a synthetic early mixed, for example, flexible fibronectin in the basement membrane in diabetic retinopathy retina (Tang, 2011).

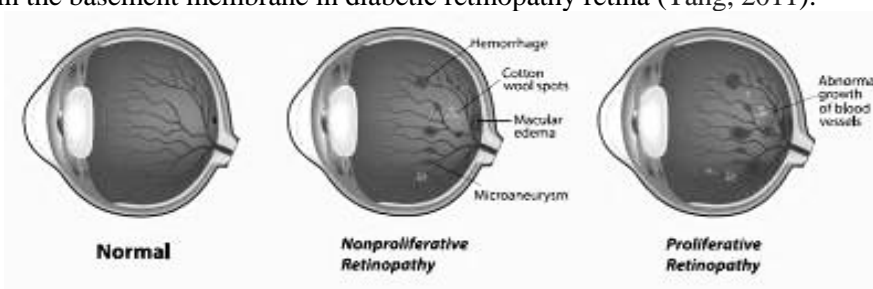


Figure.5. Abnormal Growth of Blood Vessels

Moreover, diabetes retinopathy observed immune Ross rate even collagen type I glass, II, III, IV veins and arteries laminar and fibronectin in both arterial and intravenous Comparative animal models also showed that the expression of collagen type IV and the retina increases fibronectin hyperglycemia in mice. opinion specific markers of diabetes was a base film thickness of the basement corrected mass involved in advanced stages of the disease, and diabetes retinopathy occurs, for example, the extracellular matrix of basement membrane of retinal abnormalities may lead to the accumulation of several of the components deposited on the walls of small blood vessels -C isomers., an extracellular glycoprotein expression of matrix, initially found in the stringed musical instrument and modify organs glial tissue, suggesting that it may increase the thickness of the retinal basement membrane glycoprotein's (Bello, 2014). A typical example is the pattern of blood flow in the blood vessels of the retina caused by the organization, including increased blood flow heterogeneity changes in the retina and blood flow in the retina of the eye of the distribution function of changes in the retina.

Support vector machine: Image segmentation by assembling results in a number of areas secretions filter. In order to classify secretions pixels of pixels is secretions correctly, is the use of morphological image reconstruction. This is an iterative method which is extracted from the regions of interest of the image by the repeated expansion in two forms, a sign and a mask. Let us, then, that the image is a sign that the fourth and the image mask so that $i_f < I_v$. Then the process of expansion of irrigation conditional (i_f and I_v) is given as follows: the algorithm reduces the function of the difference which is given in Equation 1. The SVM classification technique and show how it leads to the formulation of a QP programming problem in a number of variables that is equal to the number of data points. The data set is linearly separable, and to find the best hyper plane that separates the data (Hammes, 2011).

$$\min(w, b) = \frac{1}{2} \|w\|^2 \quad (1)$$

$$y_i (w^T \phi(x_i) + b) \geq 1$$

$$f_{w,b} = \frac{\text{sign}(w \cdot x + b)}{\|w\|} \leq A \quad (2)$$

Dual problem:

$$\begin{aligned} \max D &= \sum_{i=1}^n \alpha_i - \frac{1}{2} \sum_{i,j=1}^n y_i \alpha_i y_j \alpha_j \phi(x_i)^T \phi(x_j) \\ \alpha_i &\geq 0 \\ \sum_i y_i \alpha_i &= 0 \end{aligned} \quad (3)$$

The linear discriminant Function

$$\vec{y} = \sum_{i=1}^n y_i \alpha_i^* \phi(x_i)^T \phi(x) + b^* \quad (4)$$

$$\min(w, b, \xi) = \frac{1}{2} \|w\|^2 + C \sum_{i=1}^n \xi_i \quad (5)$$

$$y_i (w^T \phi(x_i) + b) \geq 1 - \xi_i$$

ξ is a slack variables C is the additional parameter that controls the compromise between the large margin and small margin.

$$\max D = \sum_{i=1}^n \alpha_i - \frac{1}{2} \sum_{i,j=1}^n y_i \alpha_i y_j \alpha_j K(x_i, x_j) \quad (6)$$

$$\vec{y} = \sum_{i=1}^n y_i \alpha_i^* K(x_i, x) + b^* \quad (7)$$

$$y_i \alpha_i \in [A_i, B_i] = (0, C) \quad \text{if } y_i = +1 \\ (-C, 0) \quad \text{if } y_i = -1 \quad (8)$$

It can represent these constraints using positive Lagrange coefficients $\alpha_i \geq 0$.

$$L(w) = \frac{1}{2} \|w\|^2 + C \sum_{i=1}^n \xi_i - \sum_{i=1}^n \alpha_i (y_i (w^T \phi(x_i) + b) - 1 + \xi_i) \quad (9)$$

$$D(\alpha) = \min L(w)$$

$$\xi_i \geq 0$$

$$\vec{D} = \sum_{i=1}^n \alpha_i - \frac{1}{2} \sum_{i,j=1}^n y_i \alpha_i y_j \alpha_j K(x_i, x_j) \quad (10)$$

$$D(\alpha) = \vec{D}(\alpha) \leq L(w) \leq P(w) \quad (11)$$

$$D(\alpha^*) = P(w^*)$$

Let $\alpha^* = (\alpha_1^*, \alpha_2^*, \alpha_3^* \dots \alpha_n^*)$ be solution of the dual problem. Obviously α^* satisfies the dual constraints. Let $d^* = (d_1^*, d_2^*, d_3^*, d_n^*)$ be the derivatives of the dual objective function in α^*

The optic disc localization and detection at the border specified in this work (Zhang, 2014). The threshold method is used frequently, followed by analysis of the connector to locate the optic disc and find the middle approximate.

Proposed Method: The optic disc, fovea bright ingredients lesion has been detected. In bright lesion detection component, is used for the optical disk location to remove any false discoveries lesion bright optical disk. Qatar used to resettle the fovea. Fovea detection component detects blood vessels and corridors, and slick fovea. Outputs are used for the diagnosis of this component diabetic retinopathy element (Nicholson, 2010). SVM has been developed based on the method of assembling a bright lesion detection to detect secretions and stains cotton wool. The outputs of these two elements of the diagnosis of diabetic retinopathy element. Designed diagnose diabetic retinopathy element to provide four levels, respectively, and diabetic retinopathy, and three levels of macular edema.

Hard exudates are abnormal lesions caused by abnormal diabetic retinopathy in the eye and diabetes. They are associated with patches of damage to the blood vessels in the retina of the eye with the leak. It is considered one of the areas the density of luminous images in the retina and yellow spots appear random. The size and distribution of secretions may vary during the progression of the disease. The segmentation is achieved secretions solid in two steps. First, it is detected secretions filter regions using the method of SVM. After this is done, the application of morphological reconstruction method to find areas exactly secretions.

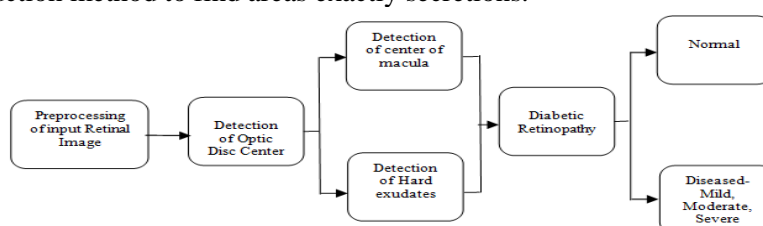


Figure.6. Automatic diabetic severity classification system.

Optical disk which has almost the same intensity as it is masked secretions during the detection process secretions to avoid false positives. For the classification of the region fragmented into secretions or excreta, are active in SVM method. Secretions will be located within the cluster higher density along with the optic disc and other pests are bright and the background in the mass range of lower density. It is scheduled centroid initial set of group secretions C_E to the limit, and the level of maximum intensity variation in image density. The centroid is assigned an initial set of C_B cluster background for a minute and the level of the minimum density variation in image density.

3. RESULTS

Diabetic maculopathy is a complication of diabetes, which is the main cause of vision loss among people all over the world. It results from leakage of fluid rich in fat and cholesterol from the blood vessels in the retina damaged. This accumulation of fluid secretions called near the center of the retina, or macula, as shown in Figure 7 leads to a distortion of central vision.

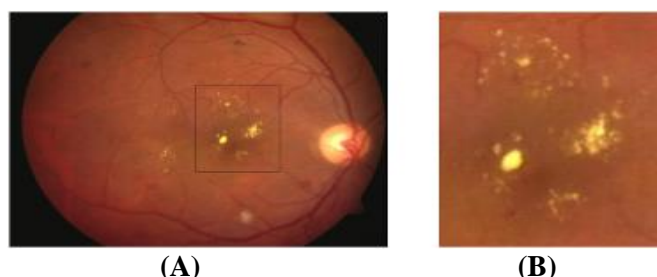


Figure.7. Diabetic maculopathy condition in colour retinal image; (a) Hard exudates in the macular region; (b) Enlarged exudates.

Development of diabetic maculopathy slow and quiet, often no symptoms in the early stages. If not detected in the early stages of macular degeneration, and the damage or visual field is not reversible, and can lead to blindness. The retinal lesion leads to a lot of checking to generate a digital image of manual analysis by experts.

This often leads to fatigue observer and an increase in the time required to diagnose the disease. System has been developed based on the analysis of the images to the bottom of the components (Silva, 2014). The system starts automatically detects the anatomical structure of the retina: blood vessels, optic disc and fovea. Then, it determines abnormalities such as excreta and solid stains cotton wool, microaneurysms and bleeding in the retina. Image exploration to the foot of the grading system, diabetic retinopathy and macular edema established on the recognition of these lesions and it also provides the spatial dissemination of defects on the basis that the fovea, such as an eye ophthalmologist can sort a detailed diagnosis. The system provides classification and images appear and diabetic retinopathy encouraging results. Performs the bottom of the image analysis system proposed in determining the best bottom images with diabetic retinopathy compared with other systems examined diabetic retinopathy recently developed with a sensitivity of 100% and specificity of 96.98% (McArthur, 2011). It also achieved the bottom of the image analysis system proposed high sensitivity and specificity are reasonable, and it can be used to assist

ophthalmologists in the examination and treatment of diabetic retinopathy.

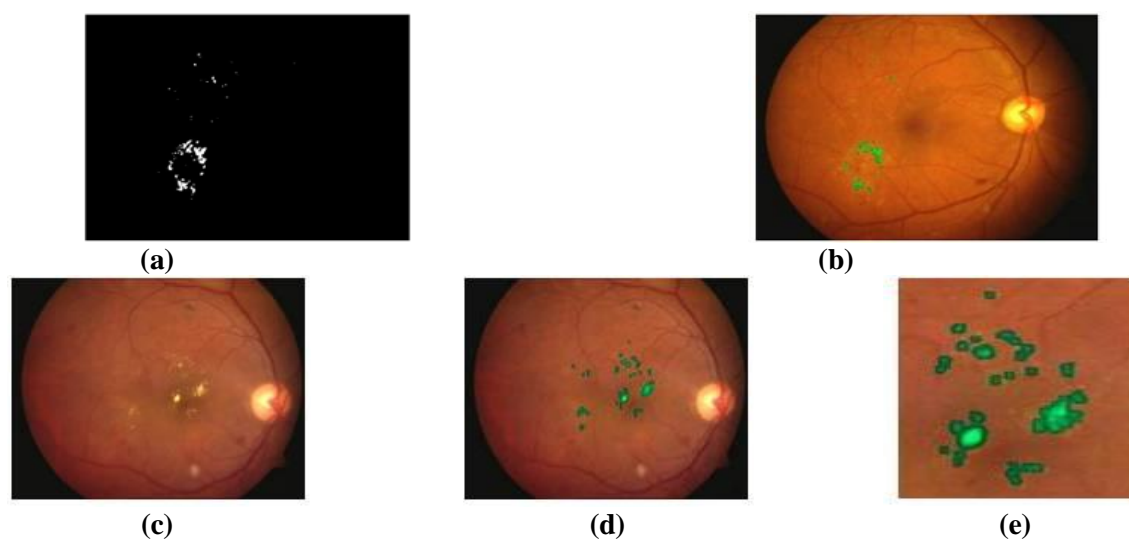


Figure.8. Fine segmentation of hard exudates; (a) Threshold exudates pixels; (b) Exudates original image; (c) Another example of colour retinal image; (d) Segmented exudates; (e) Enlarged view of detected

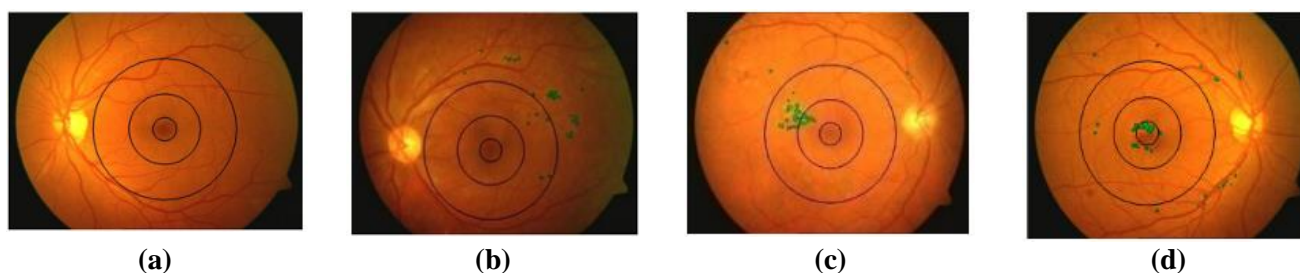


Figure.9. Severity grading (a) Normal (b) Mild stage (c) Moderate stage (d) Severe stage of maculopathy

Table.1. Early Treatment Diabetic Retinopathy Severity for Individual Eyes

Level	Severity	Definition
10	No retinopathy	Diabetic retinopathy absent
20	Very mild NPDR	Microaneurysms (Ma) only
35	Mild NPDR	Ma plus hard exudates (HE), soft exudates (cotton-wool spots) and/or mild retinal HEMORRHAGES
43	Moderate NPDR	Ma plus mild IRMA or moderate retinal hemorrhages
47	Moderate NPDR	More extensive IRMA, severe retinal hemorrhages, or venous beading in one quadrant only
53	Severe NPDR	Severe retinal hemorrhages in 4 quadrants or venous beading in at least 2 quadrants, or moderately severe IRMA in at least 1 quadrant
61	Mild PDR	NVE < 1/2 disc area in 1 or more quadrants
65	Moderate PDR	NVE ≥ 1/2 disc area in 1 or more quadrants, or NVD < 1/4-1/3 disc area
71-75	High-risk PDR	NVD ≥ 1/4-1/3 disc area and/or vitreous hemorrhage

NPDR = Non Proliferative Diabetic Retinopathy; PDR = Proliferative Diabetic Retinopathy; IRMA = Intra Retinal Micro vascular Abnormalities; NVD = New Vessels on or within 1 Disc Diameter of optic disc; NVE = New Vessels Elsewhere

This is the most sight-threatening stage of the illness the spot where vision is reduced dramatically. Figure 8 shows the results of the detection of maculopathy and automatic grading system with automated intervention (Rodrigues, 2013). It may be noted that the results provide valuable assistance to the ophthalmologist in determining the level of severity of the disease.

Coarse segmentation secretions, and that has been achieved using segmentation best initial coarse compared with contrast-based method proposed in the literature. In contrast considered cotton wool segmentation based on part of secretions (Looker, 2012). This led to the classification of sites cotton, wool and secretions in the final result. Automatic intention was also the threshold after the significant morphological reconstruction, is attained with the

entropic threshold. Existing models to inspect the retina are luxurious, and require long time and ophthalmologists trained (Simo, 2014).

The developed automated system capable to distinguish diabetes and maculopathy severity level in less time. The image data sample used to verify the authenticity of this program is similar across graders manual regarding the distribution of the severity of the disease. It also provides a user interface for quick analysis of a large number of images in the retina of the eye through a comprehensive examination of the eye disease related to diabetes (Bhavsar, 2014).

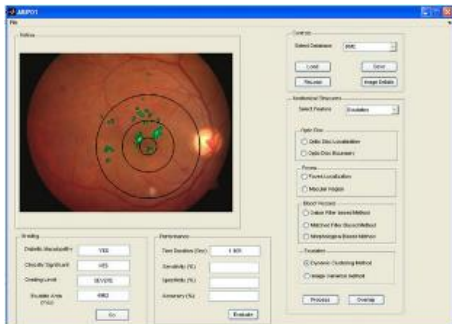


Figure.10. The automatic identification of features in colour retinal images

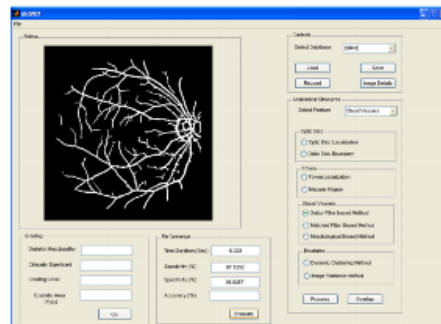


Figure.11. Marked location of macula and optic disc

It is hoped that this system can help ophthalmologists to detect signs of diabetic retinopathy at an early stage, in the monitoring of the disease and the best treatment plan (He, 2013). Among these, 0.52 they are determined normal retinal images without any signs of ill spot and 96 images as images macular-edema clinically significant by an ophthalmologist.

4. DISCUSSION AND CONCLUSION

The system identifies the fundus image analysis every important anatomical features necessary to find the approximate location and area of defect in the retina of the eye. Because of the position with detail to the normal anatomy, the crucial need of medical type of lesion related with a particular can be determined. Lesions outside the corridors of blood vessels have less urgency of lesions within the corridors of blood vessels. But these images have been included in the database to verify the robustness of the system developed. Displays the images that have suffered from non-uniform lighting and contrast of the poor for processing, before being indivisible. SVM way quickly assemble and compared with other methods based SVM in the detection of lesions and bright graph gray level of the image used in the assembly process instead of the full data of the image. This is due to consider the information in the neighborhood, it becomes a way of resisting noise. Responsible the image encloses a bright lesions, and the future approach achieves 96.61% accurateness, 100% compassion along with 88.23% specificity. Based on the assessment of the lesion, and the accuracy of 96.36%, 96.95% of compassion and specificity of 97.03%.

Future works: The retinal blood vessels used for a several purposes toruosity shows the blood vessels of the retina become a factor predictive of diabetes. Changes in retinal blood vessels toruosity may be a sign of the severity of the disease or improve. A new technique to analyze and measure toruosity by looking at the display part of the ship has to be found. To record images of the patient taken over a period of time or acquired using different methods, retinal vessel branching points can be used to control points that will be set in the two images. Embedded processors have limited computational power. Algorithms detect it simple mathematically based KNN and SVM workbooks can be loaded into them. This requires coding in assembly language. System fundus image analysis can be extended through the development of algorithms for image recording retina and detect a change in the retina, which in turn helps the eye ophthalmologist to examine the improvements last medication.

REFERENCES

Aiello L.P, Vignati L, Sheetz M.J, Zhi X, Girach A, Davis M.D, & Milton R.C, Oral Protein Kinase C β inhibition using Ruboxistaurin: Efficacy, Safety, and Causes of Vision Loss among 813 Patients (1392 eyes) with Diabetic Retinopathy in the Protein Kinase C β Inhibitor-Diabetic Retinopathy Study and the Protein kinase C β Inhibitor-Diabetic Retinopathy Study, *Retina*, 31(10), 2011, 2084-2094.

Barber AJ, Gardner TW & Abcouwer SF, The Significance of Vascular and Neural Apoptosis to the Pathology of Diabetic Retinopathy, *Investigative Ophthalmology & Visual Science*, 52(2), 2011, 1156-1163.

Bello NA, Pfeffer MA, Skali H, McGill JB, Rossert J, Olson KA & Solomon SD, Retinopathy and Clinical Outcomes in Patients with Type 2 Diabetes Mellitus, Chronic Kidney Disease, and Anemia, *BMJ Open Diabetes Research & Care*, 2(1), 2014, 1-7.

Bhavsar AR, Torres K, Glassman, A.R, Jampol L.M, & Kinyoun J.L, Evaluation of Results 1 Year Following Short-term Use of Ranibizumab for Vitreous Hemorrhage Due to Proliferative Diabetic Retinopathy, *JAMA Ophthalmology*, 132(7), 2014, 889-890.

Colagiuri S, Lee C.M, Wong, T.Y, Balkau B, Shaw J.E, & Borch-Johnsen, K, Glycemic Thresholds for Diabetes-Specific Retinopathy Implications for Diagnostic Criteria for Diabetes, *Diabetes Care*, 34(1), 2011, 145-150.

Hammes H.P, Feng Y, Pfister F, & Brownlee M, Diabetic Retinopathy, Targeting Vasoregression, *Diabetes*, 60(1), 2011, 9-16.

He F, Xia X, Wu XF, Yu XQ, & Huang FX, Diabetic retinopathy in Predicting Diabetic Nephropathy in Patients with Type 2 Diabetes and Renal Disease: a Meta-Analysis, *Diabetologia*, 56(3), 2013, 457-466.66.

Looker H.C, Nyangoma S.O, Cromie D, Olson J.A, Leese G. P, Black M, & Colhoun H. M, Diabetic retinopathy at Diagnosis of Type 2 Diabetes in Scotland, *Diabetologia*, 55(9), 2012, 2335-2342.

McArthur K, Feng B, Wu Y, Chen S, & Chakrabarti S, MicroRNA-200b Regulates Vascular Endothelial Growth Factor-Mediated Alterations in diabetic Retinopathy, *Diabetes*, 60(4), 2011, 1314-1323.

Morita H, & Nagai R, Retinopathy Progression in Type 2 Diabetes, *New England Journal of Medicine*, 363(22), 2010, 2171-2174.

Nicholson BP, & Schachat AP, A review of clinical trials of anti-VEGF agents for Diabetic Retinopathy, *Graefes Archive for Clinical and Experimental Ophthalmology*, 248(7), 2010, 915-930.

Rodrigues M, Xin X, Jee K, Babapoor-Farrokhran S, Kashiwabuchi F, Ma T & Sodhi A, VEGF Secreted by Hypoxic Müller Cells Induces MMP-2 Expression and Activity in Endothelial Cells to Promote Retinal Neovascularization in Proliferative Diabetic Retinopathy, *Diabetes*, 62(11), 2013, 3863-3873.

Silva PS, Cavallerano JD, Tolls D, Omar A, Thakore K, Patel B, & Aiello LP, Potential Efficiency Benefits of Nonmydriatic Ultrawide Field Retinal Imaging in an Ocular Telehealth Diabetic Retinopathy Program, *Diabetes care*, 37(1), 2014, 50-55.

Simó R, Sundstrom JM, & Antonetti DA, Ocular anti-VEGF therapy for Diabetic Retinopathy: The Role of VEGF in the Pathogenesis of Diabetic Retinopathy. *Diabetes Care*, 37(4), 2014, 893-899.

Sun JK, Keenan HA, Cavallerano J.D, Asztalos B.F, Schaefer E.J, Sell D.R & King, G.L, Protection from Retinopathy and Other Complications in Patients with Type 1 Diabetes of Extreme Duration the Joslin 50-Year Medalist Study, *Diabetes Care*, 34(4), 2011, 968-974.

Tang J, & Kern TS, Inflammation in Diabetic Retinopathy, *Progress in Retinal and Eye Research*, 30(5), 2011, 343-358.

Yau JW, Rogers SL, Kawasaki R, Lamoureux EL, Kowalski JW, Bek T, & Wong T.Y, Global Prevalence and Major Risk Factors of Diabetic Retinopathy, *Diabetes care*, 35, 2012, 556-564

Zhang X, Saaddine JB, Chou CF, Cotch MF, Cheng YJ, Geiss LS, & Klein R, Prevalence of Diabetic Retinopathy in the United States, 2005-2008, *The Journal of the American Medical Association*, 304(6), 2010, 649-656.

Zhang X, Wang N, Schachat AP, Bao S, & Gillies MC, Glucocorticoids, Structure, Signaling and Molecular Mechanisms in the Treatment of Diabetic Retinopathy and Diabetic Macular Edema, *Current molecular medicine*, 14(3), 2014, 376-384.